

**ORTHODONTICS AND ITS IMPACT ON SLEEP QUALITY CAUSED BY OBSTRUCTIVE APNEA****ORTODONTIA E SEU IMPACTO NA QUALIDADE DO SONO CAUSADO PELA APNEIA OBSTRUTIVA****LA ORTODONCIA Y SU IMPACTO EN LA CALIDAD DE SUEÑO CAUSADO POR LA APNEA OBSTRUCTIVA**

Yanderin Nicole Apolo Carrión¹, Carla Jessenia Rodríguez Robles¹, Nancy Pilar Sauca Chalán¹, Mateo Eduardo Ordóñez Nieto¹, Maria Yolanda Yunga Picón², Mónica Beatriz Dávila Arcentales², Milton Fabricio Lafebre Carrasco²

e42357

<https://doi.org/10.47820/recisatec.v4i2.357>

RECEIVED: 05/24/2024

APPROVED: 06/24/2024

PUBLISHED: 07/09/2024

ABSTRACT

Obstructive sleep apnea (OSA) is a respiratory disorder characterized by episodes of partial and/or complete obstruction during sleep, where breathing is interrupted or becomes shallow, resulting in decreased oxygen in the blood and micro-arousals that fragment sleep. The objective is to understand the connection between orthodontic or orthopedic treatments and the improvement they produce in this disorder. Identify the causes and consequences of obstructive sleep apnea in patients, as well as the effects of orthodontic treatments used to improve the condition. The search was conducted in PubMed, Scielo, Google Scholar, and Springerlink; MeSH terms "Sleep Apnea, Obstructive/therapy" AND Orthodontics.

KEYWORDS: Obstructive sleep apnea. Polysomnography. Rapid maxillary expansion.

RESUMO

A apneia obstrutiva do sono (AOS) é um distúrbio respiratório caracterizado por episódios de obstrução parcial e/ou completa durante o sono, onde a respiração é interrompida ou se torna superficial, resultando em uma diminuição do oxigênio no sangue e microdespertares que fragmentam o sono. O objetivo é compreender a conexão entre os tratamentos ortodônticos ou ortopédicos e a melhora que produzem nesse distúrbio. Identificar as causas e as consequências da apneia obstrutiva do sono nos pacientes, bem como os efeitos dos tratamentos ortodônticos utilizados para melhorar a doença. A busca foi realizada no PubMed, Scielo, Google Acadêmico e Springerlink; termos MeSH "Sleep Apnea, Obstructive/therapy" AND Orthodontics.

PALAVRAS-CHAVE: Apneia obstrutiva do sono. Polissonografia. Expansão rápida da maxila.

RESUMEN

La apnea obstructiva del sueño (AOS) es un trastorno respiratorio caracterizado por episodios de obstrucción parcial y/o completa durante el sueño, donde la respiración se interrumpe o se vuelve superficial, lo que resulta en una disminución del oxígeno en sangre y microdespertares que fragmentan el sueño. El objetivo es comprender la conexión entre los tratamientos ortodónticos u ortopédicos y la mejoría que producen en este trastorno. Identificar las causas y consecuencias de la apnea obstructiva del sueño en los pacientes, así como los efectos de los tratamientos ortodónticos utilizados para mejorar la enfermedad. La búsqueda se realizó en PubMed, Scielo, Google Scholar y Springerlink; Términos MeSH "Apnea del Sueño, Obstructivo/terapia" Y Ortodoncia.

PALABRAS CLAVE: Apnea obstructiva del sueño. Polissonografía. Rápida expansión de la mandíbula.

¹ Estudiante de la Facultad de Odontología - Universidad de Cuenca.

² Docente titular de la Facultad de Odontología de la Universidad de Cuenca-Ecuador.

RECISATEC – REVISTA CIENTÍFICA SAÚDE E TECNOLOGIA ISSN 2763-8405

ORTHODONTICS AND ITS IMPACT ON SLEEP QUALITY CAUSED BY OBSTRUCTIVE APNEA
Yanderin Nicole Apolo Carrión, Carla Jessenia Rodríguez Robles, Nancy Pilar Sauca Chalán, Mateo Eduardo Ordóñez Nieto,
María Yolanda Yunga Picón, Mónica Beatriz Dávila Arcentales, Milton Fabricio Lafebre Carrasco

INTRODUCTION

Obstructive sleep apnea (OSA) is a chronic and progressive respiratory disorder with serious systemic repercussions, affecting millions of people globally. OSA is characterized by repetitive episodes of respiratory arrest during sleep due to obstruction of the upper airways (UAS) given by recurrent collapse of the pharyngeal region as a result of a posterior position of the tongue, which causes a significant reduction in air flow into the lungs during sleep for approximately 10 seconds (1,9).

As it is a complex pathology with an increasing prevalence, the role of both the general dentist and the orthodontic specialist is significant in the detection of initial signs and symptoms, as well as in the treatment of OSA through the use of intraoral devices (DIO) that improve respiratory function, and therefore, improve the patient's quality of life. In this way, we can refer patients in a timely manner, have treatment alternatives with an interdisciplinary vision and optimize treatment strategies in clinical practice (1,12).

Intraoral devices can help improve posture and breathing during sleep, which may reduce OSA symptoms. It is necessary to thoroughly investigate how orthodontic appliances can contribute to treating OSA and the partial or total suppression of snoring, which, when correctly manufactured and indicated, can improve the quality of life of affected patients (3,5).

The purpose of this study was to evaluate the effectiveness of intraoral appliances in improving OSA in children and adults.

Obstructive Sleep Apnea Syndrome

OSA is characterized by episodes of partial and/or complete obstruction during sleep where breathing is interrupted or becomes shallow, for a minimum of 10 seconds resulting in a decrease in oxygen in the blood and micro awakenings that fragment sleep (1,13).

Obstruction of the airway produces hypoxemia, hypercapnia and increased respiratory effort, which increases the risk of developing cardiac problems. Currently, OSA is considered a public health problem due to its fatal potential (4).

Etiology and risk factors

OSA is a multifactorial disease that results in anatomical changes in the upper airway and craniofacial skeleton associated with neuromuscular changes in the pharynx. Among the various factors that increase the risk of suffering from OSA are advanced age, family history, heart or kidney failure, enlarged tonsils, lifestyle, craniofacial anomalies such as: maxillomandibular hypoplasia, increase in pharyngeal lymphoid tissue, greater fat deposition in the neck area which can block the VAS (3,5,6).

It is more prevalent in adulthood but can also occur in young individuals under 18 years of age. OSA in children is less common and its etiology is multifactorial. In children who do not suffer from any syndrome or comorbidity, the main etiological factor is hypertrophy of the tonsils and adenoids, other

RECISATEC – REVISTA CIENTÍFICA SAÚDE E TECNOLOGIA ISSN 2763-8405

ORTHODONTICS AND ITS IMPACT ON SLEEP QUALITY CAUSED BY OBSTRUCTIVE APNEA
Yanderin Nicole Apolo Carrión, Carla Jessenia Rodríguez Robles, Nancy Pilar Sauca Chalán, Mateo Eduardo Ordóñez Nieto,
María Yolanda Yunga Picón, Mónica Beatriz Dávila Arcentales, Milton Fabricio Lafebre Carrasco

less frequent factors are narrow upper airways resulting in an elongated face, constriction of the maxilla, deep palate and different degrees of retrusion. mandibular (4,10).

Symptoms

A history of snoring, shortness of breath or choking, and pauses in breathing (apneas) during sleep are common in adult patients with OSA. Frequent night awakenings, loud snoring, unrefreshing sleep, morning headaches and excessive daytime sleepiness, problems with attention and concentration, mood disturbances and difficulty controlling other medical comorbidities such as diabetes mellitus, hypertension and obesity are some of the most common clinical symptoms of untreated OSA (7,8).

Pediatric patients sleep in unusual positions, such as with the neck hyperextended or the head hanging off the side of the bed, in addition to appearing very restless with frequent position changes during sleep. Some individuals may experience drowsiness, while others may experience hyperactivity rather than excessive sleepiness (4,6).

DIAGNOSIS

The diagnosis is made based on a complete clinical history compatible with the presence of symptoms of excessive daytime sleepiness, unrefreshing sleep, morning headaches, cognitive impairment, among others, as well as nighttime snoring and nocturnal apneic episodes. The doctor will be the professional in charge of identifying the condition and severity of OSA so that he can prevent serious complications such as hypertension or cardiovascular diseases, as well as improve the quality of life of patients (7,23,24).

While, in children, early diagnosis and treatment of OSA is essential to avoid an impact on their neurocognitive abilities, academic performance, behavior and cardiovascular system that will have a great influence on the child's quality of life (6,8).

Furthermore, important data such as age, overweight, especially if the patient's BMI is greater than 30, family or personal medical history are collected in the medical history. It leads the treating physician to an initial suspicion and may suggest different diagnostic tests (9,24,28).

In addition, accompanied by a thorough medical history, a clinical examination should be performed and blood pressure, respiratory, masticatory, neurological, cardiac, and hematological systems evaluated. Any maxillofacial malformation, overbite or overbite, tooth anomalies, malocclusion, mandibular deviations and TMJ alterations should be observed during the clinical dental examination. The size and consistency of the tongue, presence or absence of pharyngeal edema or an unusual reddish color, the appearance of the soft palate, the size, length and position of the uvula, the presence or absence of lymphoid tissue and alterations of the nose (24,28).

RECISATEC – REVISTA CIENTÍFICA SAÚDE E TECNOLOGIA ISSN 2763-8405

ORTHODONTICS AND ITS IMPACT ON SLEEP QUALITY CAUSED BY OBSTRUCTIVE APNEA
Yanderin Nicole Apolo Carrión, Carla Jessenia Rodríguez Robles, Nancy Pilar Sauca Chalán, Mateo Eduardo Ordóñez Nieto,
María Yolanda Yunga Picón, Mónica Beatriz Dávila Arcentales, Milton Fabricio Lafebre Carrasco

History and clinical examination

By using the medical history, the patient or her partner/parent/guardian can alert them to symptoms such as loud snoring, excessive daytime sleepiness, unrefreshing sleep, among others. Furthermore, important data such as age, overweight, especially if the patient's BMI is greater than 30, family or personal medical history are collected in the medical history. This set of data leads the treating physician to an initial suspicion and may suggest different diagnostic tests (9).

In addition, accompanied by a thorough medical history, a clinical examination should be performed and blood pressure, respiratory, masticatory, neurological, cardiac, and hematological systems evaluated. Any maxillofacial malformation, overbite or overbite, tooth anomalies, malocclusion, mandibular deviations and TMJ alterations should be observed during the clinical dental examination. The size and consistency of the tongue, presence or absence of pharyngeal edema or an unusual reddish color, the appearance of the soft palate, the size, length and position of the uvula, the presence or absence of lymphoid tissue and alterations of the nose (14).

Polysomnography

Laboratory polysomnography (PSG) is the gold standard for the diagnosis of OSA in children, adolescents, and adults, because questionnaires and history alone are not suitable in clinical practice (28).

PSG records various physiological parameters during sleep, monitoring breathing, oxygen levels, snoring, different stages of sleep, the number of hypopneas and apneas, as well as their index. It should be used whenever possible (31).

Imaging studies

Lateral cephalic radiography is a low-cost method where the patient receives minimal radiation and allows us to visualize the narrowing of the pharynx, which is the most common finding in children, adolescents and adults with OSA. Skeletal differences in patients with OSA are reported in the sagittal plane where cephalometric variables such as SNA, SNB and ANB are used, which indicate a tendency to retrusion of the anterior base of the skull, mandible and inferior position of the hyoid bone that produces a decrease in VAS. Airway narrowing increases the probability of predicting OSA (11,29).

Although two-dimensional images are very useful, the complexity of the airways requires three-dimensional imaging techniques that allow us to evaluate the upper airways in an anteroposterior and not a transverse plane. Computed tomography (CT) and MRI are very useful three-dimensional imaging tools, however, the radiation of CT and the high cost of MRI indicate the search for a more suitable alternative (11,14,26).

The use of cone beam computed tomography (CBCT) is advantageous due to its short scanning time (10-70 seconds) and low radiation dose compared to conventional CT. CBCT may indicate findings that imply early referral of suspected OSA patients for further evaluation. Generally, the region of interest

RECISATEC – REVISTA CIENTÍFICA SAÚDE E TECNOLOGIA ISSN 2763-8405

ORTHODONTICS AND ITS IMPACT ON SLEEP QUALITY CAUSED BY OBSTRUCTIVE APNEA
Yanderin Nicole Apolo Carrión, Carla Jessenia Rodríguez Robles, Nancy Pilar Sauca Chalán, Mateo Eduardo Ordóñez Nieto,
María Yolanda Yunga Picón, Mónica Beatriz Dávila Arcentales, Milton Fabricio Lafebre Carrasco

for the evaluation of OSA is to identify the position of the hyoid bone that supports the insertion of the mylohyoid muscle that contributes to the position of the jaw and affects the position of the tongue (6,14).

Severity

According to the American Academy of Sleep Medicine, OSA is classified as mild, moderate or severe according to the Apnea-Hypopnea Index (AHI), which refers to the number of times per hour that breathing stops or decreases significantly during sleep. is the basis of this classification. From 5 to 14 is considered mild, from 15 to 29 moderate and greater than 30 severe (4).

Prevalence

It affects 3% of women and 10% of men between 30 and 49 years of age and can increase to 9% and 17% respectively between 50 and 70 years of age (Solomon et al., 2019).

The Latin American and Asian population has a higher incidence of OSA than the European or North American population. In Santiago de Chile the prevalence was 8.8% and 5%, in Mexico 4.4% and 2.4%, Montevideo 3.7% and 0.5%, Caracas 1.5% and 2.4% respectively in men and women (Menezes et al., 2005).

Prevalence rates are higher in some populations, such as obese patients with a body mass index (BMI) greater than 28 and male patients are three times more likely than female patients (Laratta et al., 2017).

TREATMENT

Continuous positive airway pressure

Continuous positive airway pressure (CPAP) is a treatment of choice in OSA because it corrects respiratory events, thereby improving sleep quality and excessive daytime sleepiness. It is a machine that pumps pressurized air into the airways, keeping them open during sleep, preventing them from collapsing and causing apnea. CPAP is recommended for people with moderate to severe OSA, people who cannot tolerate intraoral devices, and people with heart and lung disease (15,27,31).

The use of CPAP in children is a second-line treatment behind AT. CPAP treatment is most useful in residual OSA, children with obesity, craniofacial disorders or neuromuscular diseases (15,16).

Intraoral devices

According to the mechanism of action, we can differentiate DIOs into three groups (7):

- Elevators of the soft palate
- Lingual retainers
- Mandibular advancement devices (MAD)

RECISATEC – REVISTA CIENTÍFICA SAÚDE E TECNOLOGIA ISSN 2763-8405

ORTHODONTICS AND ITS IMPACT ON SLEEP QUALITY CAUSED BY OBSTRUCTIVE APNEA
Yanderin Nicole Apolo Carrión, Carla Jessenia Rodríguez Robles, Nancy Pilar Sauca Chalán, Mateo Eduardo Ordóñez Nieto,
María Yolanda Yunga Picón, Mónica Beatriz Dávila Arcentales, Milton Fabricio Lafebre Carrasco

Elevators of the soft palate

They act as a bridge by raising the soft palate, the uvula is located on a more superior plane so that it attenuates the vibration generated by the passage of air during sleep and which is the main cause of snoring. It can be used in patients who underwent soft tissue surgery with OSA and patients with snoring. We can differentiate two types of devices (7):

- ASPL (Adjustable Soft Palate Lifter): this is a removable acrylic maxillary plate that in its posterior and middle part has an acrylic button that moves distally with the use of an activation screw. The device requires the patient to activate it 1/8" each night, until the acrylic button reaches the soft palate area, which is the most clinically effective area (15).
- Equalizer (Equalizer Airway Device): can be considered as a soft palate elevator and as an anterior jaw repositioner. It has two plastic tubes in its anterior part, so that its objective is to equalize the intraoral and extraoral air pressure, without harming nasal breathing. Anchoring systems can be added to increase the degree of retention in the mouth (15,19).

Lingual retainers

They keep the tongue in a more forward position without mandibular advancement. Thus, by increasing the distance between the tongue and the posterior pharyngeal wall, the posterior airspace increases. Its use is intended for patients with dental problems such as insufficient protrusion or lack of supporting teeth who are not candidates for MAD or can be used in conjunction with MAD for a lesser amount of mandibular advancement (7).

- TRD (Tongue Retaining Device): used in completely edentulous patients. This device consists of an acrylic anterior bulb that creates a negative position inside when the tongue is inserted during sleep and therefore the tongue is kept in a forward position by suction (19,29).
- TLD (Tongue Locking Device): its design is inferior to the TRD, but it still exerts a traction effect on the tongue to a more forward position (19).

Mandibular advancement devices (MAD)

They are the most commonly used DIOs as a treatment for OSA. They act by producing a mandibular advancement that achieves an anterior repositioning of the tongue and soft palate, due to the superior displacement of the hyoid bone, lateral of the parapharyngeal fat pads and anterior of the muscles of the base of the tongue. As a result, changes are induced in the morphology and volume of the VAS. Currently, on the market there are a variety of prefabricated or laboratory MADs, "boil and bite", monoblock or biblock, adjustable or non-adjustable, rigid or soft material (15,29,32).

The use of orthodontic appliances is recommended for patients with mild to moderate OSA who do not respond favorably to CPAP. These devices improve the alignment of the jaw, palate, and tongue position, which can reduce the risk of airway obstruction during sleep. Orthodontic devices fall into two main categories: First, mandibular advancement devices (MADs) are the most common and work by

RECISATEC – REVISTA CIENTÍFICA SAÚDE E TECNOLOGIA ISSN 2763-8405

ORTHODONTICS AND ITS IMPACT ON SLEEP QUALITY CAUSED BY OBSTRUCTIVE APNEA
Yanderin Nicole Apolo Carrión, Carla Jessenia Rodríguez Robles, Nancy Pilar Sauca Chalán, Mateo Eduardo Ordóñez Nieto,
María Yolanda Yunga Picón, Mónica Beatriz Dávila Arcentales, Milton Fabricio Lafebre Carrasco

protruding the jaw to help open the airway. In those patients who do not tolerate MADs, tongue repositioning devices (TDRs) are used, which prevent the tongue from being placed in a posterior position and help open the airway (14,15,31).

Rapid maxillary expansion

Rapid maxillary expansion (RME) is a dentofacial orthopedic treatment used in young patients for the treatment of maxillary arch constriction. It aims to open the midpalatal suture and adjacent skeletal structures, and not only allow tooth movement in the alveolar bone, but also increase adequate and stable maxillary width. Its short-term effectiveness has been demonstrated with the use of a rapid maxillary expander and with evidence of an improvement in OSA (8,12).

Two common methods are used for palatal disjunction of the maxilla: appliances that are supported solely on the teeth by bands, such as Hyrax, or cemented with acrylic tracks on the occlusal surface, and appliances that have mixed tooth and acrylic support on the palatal mucosa. These techniques have more skeletal effect because they transmit force more directly to the palatine vault. Expansion screw circuit breakers have the ability to produce a molar expansion of 4.69 mm to 7.9 mm. After cementation of the maxillary rapid expander, activation begins immediately. It is turned daily for 30 to 40 days to modify the midpalatal suture and other sutural areas, which causes the appearance of a diastema characteristic of maxillary expansion (15,21,24).

An improvement in sleep apnea and better ventilation is notable, which is due to reasons such as the increase in the dimension of the pharynx, the indirect improvement of the oropharyngeal space due to the modification of the resting position of the tongue, the changes in anatomical structures, increased nasal airflow, significant improvement in nasopharyngeal function and reduction of nasorespiratory problems (16,17).

Surgical treatment

There are various types of surgical procedures that can be performed to improve OSA. Nasal surgery is included, which is effective in improving sleepiness, but not in improving AHI, and also improves the acceptance and tolerance of CPAP. Tonsillar surgery is indicated in cases where there is marked hypertrophy, while palatopharyngeal surgery is indicated in patients where there is evidence of collapse in the palate (18,21).

In children, the surgical procedure that removes the tonsils and adenoids is known as adenotonsillectomy (AT) and is a primary treatment for treating cases of airway obstruction and sleep apnea. In healthy children this procedure has beneficial results, however, 20% of children have OSA refractory to AT due to variables such as asthma, obesity, craniofacial anomalies, severe AHI. Along with the treatment, the use of corticosteroids, myofunctional therapy, weight loss, rapid maxillary expansion (RME) or combined interventions (18,19).

RECISATEC – REVISTA CIENTÍFICA SAÚDE E TECNOLOGIA
ISSN 2763-8405

ORTHODONTICS AND ITS IMPACT ON SLEEP QUALITY CAUSED BY OBSTRUCTIVE APNEA
 Yanderin Nicole Apolo Carrión, Carla Jessenia Rodríguez Robles, Nancy Pilar Sauca Chalán, Mateo Eduardo Ordóñez Nieto,
 María Yolanda Yunga Picón, Mónica Beatriz Dávila Arcentales, Milton Fabricio Lafebre Carrasco

The role of the orthodontist in OSA

The dentist intervenes in the detection and diagnosis of OSA because he can notice the symptoms during routine visits that can be reported by the patient or his partner or representative during the anamnesis, as well as signs observed during the intraoral examination, the most frequent being retrognathia, elongated soft palate or tonsillar hypertrophy. In addition, it intervenes in the evaluation of oral health, possible dental complications in relation to OSA, and monitoring the patient (5,16,20).

MATERIALS AND METHODS

A bibliographic search was carried out in the following databases: PubMed, Scielo, Science Direct, Google Scholar and Springerlink. The keywords were selected taking into account the medical term MeSH and the health sciences descriptors DeCS, the terms selected for the search were: Sleep Apnea, Obstructive/therapy, AND Orthodontics.

The search included articles published from 2014 to 2024, in English and Spanish.

As inclusion criteria, second-order cases were reviewed, such as: cohort studies, cases and controls, and first-order cases, such as: systematic reviews and meta-analysis. The articles and scientific information that are in the languages: Spanish, English and Portuguese were taken into account, that have a publication range of 10 years or less and that have free access to all the information, as exclusion criteria are those studies duplicates and dealing with the same topic.

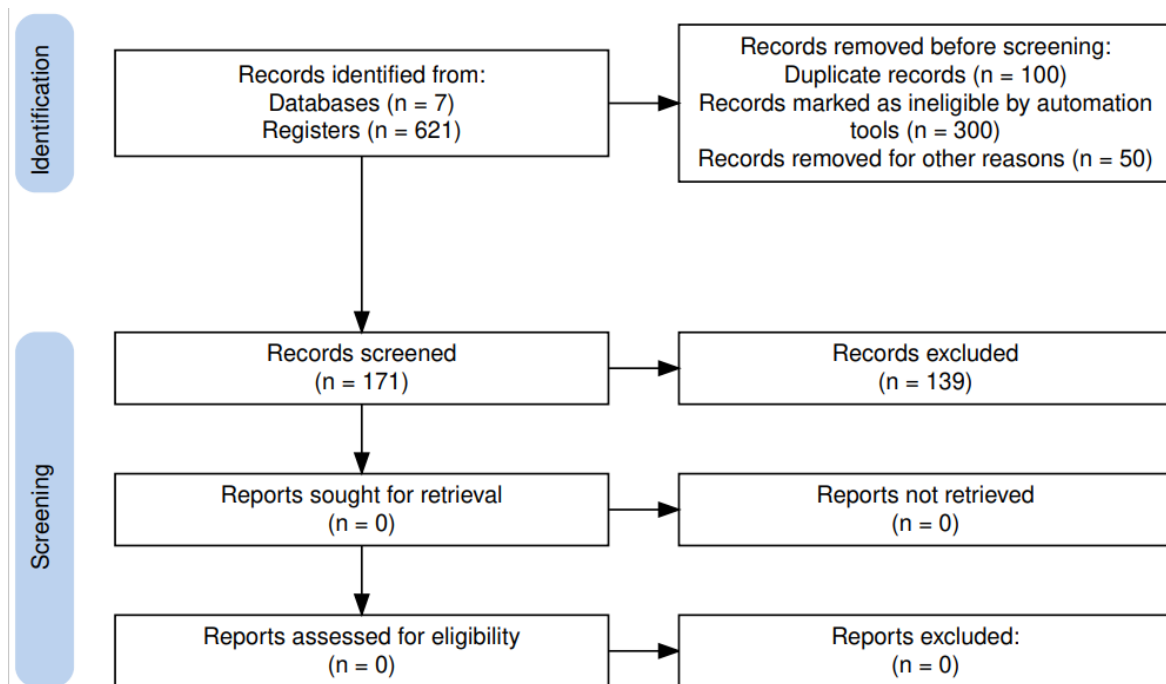


Figure 1. PRISMA flow chart (18)

RECISATEC – REVISTA CIENTÍFICA SAÚDE E TECNOLOGIA ISSN 2763-8405

ORTHODONTICS AND ITS IMPACT ON SLEEP QUALITY CAUSED BY OBSTRUCTIVE APNEA
Yanderin Nicole Apolo Carrión, Carla Jessenia Rodríguez Robles, Nancy Pilar Sauca Chalán, Mateo Eduardo Ordóñez Nieto,
María Yolanda Yunga Picón, Mónica Beatriz Dávila Arcentales, Milton Fabricio Lafebre Carrasco

CONSIDERATIONS

OSA is a multifactorial disease, being the most complex manifestation in the panorama of breathing disorders during sleep. To detect cases in children or adults, it is essential to be very cautious when identifying signs and symptoms. Likewise, the pathophysiology of the disease must be understood in order to ensure adequate care for these cases.

It is recommended that orthodontists become strongly familiar with the signs and symptoms of OSA, because during orthodontic treatment dentists frequently observe their patients, which is why they could identify individuals at high risk of OSA efficiently and early.

An early diagnosis is essential in children with narrowing of the upper airways so that correct mandibular development occurs and also to avoid future damage to the patient, such as an impact on neurocognitive skills, academic performance, behavior and the cardiovascular system that will have great influence. in quality of life.

Oral plates are an important tool in the treatment of OSA, such as the mandibular advancement device, which corrects the symptoms and severity of the disease, obtaining benefits by promoting facial and dentoalveolar changes.

However, more testing is needed to confirm that orthodontics and orthopedics can improve the disease, and a more robust care protocol is also required to determine which treatment is most appropriate for each patient based on the severity of the condition. disease, the age of the patient and the etiology of the disease.

DISCUSSION

Obstructive sleep apnea is a breathing disorder characterized by episodes of partial and/or complete obstruction during sleep where breathing is interrupted or becomes shallow, resulting in a decrease in oxygen in the blood and micro-arousals that fragment sleep. . When determining treatment options for patients with obstructive sleep apnea, a thorough review of the patient's comorbidities, including maxillofacial and oral restrictions, is essential. Intraoral devices emerge as a treatment alternative due to their simplicity, reversibility and acceptance by the patient with respect to other treatments. Among the most used currently we have elevators of the soft palate, lingual retainers and mandibular advancement devices.

In 2017, Fernández et al. in their case-control study compared the effectiveness of intraoral devices, finding that mandibular advancement devices are an appliance of choice in the treatment of mild to moderate OSA due to their ability to reduce snoring and nausea. sleep apneas, its installation is simple and small in size, the device must provide sufficient mandibular protrusion to keep the airway clear.

Regarding MAD + CPAP as a treatment for OSA, it is a combined therapy between a mandibular advancement device and a continuous positive airway pressure system, an alternative indicated in cases of nasal obstruction with moderate to severe OSA. In the study by Marklund 2014, which

RECISATEC – REVISTA CIENTÍFICA SAÚDE E TECNOLOGIA ISSN 2763-8405

ORTHODONTICS AND ITS IMPACT ON SLEEP QUALITY CAUSED BY OBSTRUCTIVE APNEA
Yanderin Nicole Apolo Carrión, Carla Jessenia Rodríguez Robles, Nancy Pilar Sauca Chalán, Mateo Eduardo Ordóñez Nieto,
María Yolanda Yunga Picón, Mónica Beatriz Dávila Arcentales, Milton Fabricio Lafebre Carrasco

examined a total of 75 patients, who used DAM the results showed highly significant reductions in the apnea hypopnea index (from 44 to 12 events per hour) and a high response of 81% of patients, in achieving a 50% reduction in AHI.

Orthodontic appliances and removable functional appliances help improve upper airway patency during sleep, increase muscle tone by expanding and decreasing upper airway collapse.

FOA therapy should be recommended in pediatric OSA, and if performed with an early approach, can permanently change respiration and nasal breathing, thereby preventing upper airway obstruction.

According to the heterogeneity of the included studies, regardless of the type of device used and the protocol followed, a decrease in the AHI index was observed after treatment, with reports of improvement in daytime sleepiness and sleep quality, decrease in snoring and mouth breathing and promotion of increased pharyngeal dimensions and beneficial cephalometric changes.

Functional appliances can be considered very effective in the treatment of children with OSA, but more randomized studies with larger sample sizes involving a representative number of patients with apnea and malocclusion are necessary to establish protocols related to the time of use of the appliance. per day, duration of treatment and long-term comparison of the effects of different types of FOA.

BIBLIOGRAPHIC REFERENCES

1. Síndrome de apnea obstructiva del sueño: Revisión de la literatura. Revista Latinoamericana de Ortodoncia y Odontopediatría. 2020. Disponible en: <https://www.ortodoncia.ws/publicaciones/2020/art-51/>.
2. Alvarado MJ, Oyonarte R. Apnea Obstructiva del Sueño y el Rol del Ortodoncista. Revisión bibliográfica. Int j interdiscip dent [Internet]. 2021;14(3):242–5. Disponible en: <http://dx.doi.org/10.4067/s2452-55882021000300242>
3. Alzate MAB, Zafra LA, Fajardo IGS. El papel del odontólogo en la intervención de la apnea obstructiva del sueño. Revista CES Odontología [Internet]. 2020;33(2):128–35. Available from: http://www.scielo.org.co/scielo.php?script=sci_arttext&pid=S0120-971X2020000200128
4. American Thoracic Society. Epidemiology of Pediatric Obstructive Sleep Apnea | Proceedings of the American Thoracic Society [Internet]. Available from: <https://www.atsjournals.org/doi/full/10.1513/pats.200708-135MG?journalCode=pats>
5. Anitua E, Cobo J, De Carlos F, González M, Macias E, Monasterio C, et al. Guía española de práctica clínica utilización de los dispositivos de avance mandibular (DAM) en el tratamiento de pacientes adultos con síndrome de apneas-hipopneas del sueño [Internet]. [s. l.; s. n]; 2017. Ilus, Tab. BIGG. 2017. Available from: <https://pesquisa.bvsalud.org/portal/resource/pt/biblio-964101>
6. Attali V, Chaumereuil C, Arnulf I, Golmard JL, Tordjman F, Morin L, et al. Predictors of long-term effectiveness to mandibular repositioning device treatment in obstructive sleep apnea patients after 1000 days. Sleep Medicine [Internet]. 2016;27–28:107–14. Available from: <https://pubmed.ncbi.nlm.nih.gov/27938910/>

RECISATEC – REVISTA CIENTÍFICA SAÚDE E TECNOLOGIA ISSN 2763-8405

ORTHODONTICS AND ITS IMPACT ON SLEEP QUALITY CAUSED BY OBSTRUCTIVE APNEA
Yanderin Nicole Apolo Carrión, Carla Jessenia Rodríguez Robles, Nancy Pilar Sauca Chalán, Mateo Eduardo Ordóñez Nieto,
María Yolanda Yunga Picón, Mónica Beatriz Dávila Arcentales, Milton Fabricio Lafebre Carrasco

7. Bartolucci ML, Bortolotti F, Raffaelli E, D'Antò V, Michelotti A, Bonetti GA. The effectiveness of different mandibular advancement amounts in OSA patients: a systematic review and meta-regression analysis. *Sleep & Breathing* [Internet]. 2016;20(3):911–9. Available from: <https://pubmed.ncbi.nlm.nih.gov/26779903/>
8. Bariani RC, Badreddine FR, Yamamoto LH, Shido FT, Hoppe DPMR, Tufik S, et al. Rapid maxillary expansion in patient with obstructive sleep apnea: case report. *Sleep Science* [Internet]. 2022;15(S 01):293–9. Available from: <https://www.ncbi.nlm.nih.gov/pmc/articles/PMC8889987/>
9. Behrents RG, Shelgikar AV, Conley RS, Flores-Mir C, Hans M, Levine M, et al. Obstructive sleep apnea and orthodontics: An American Association of Orthodontists White Paper. *Am J Orthod Dentofacial Orthop* [Internet]. 2019;156(1):13-28.e1. Disponible en: <http://dx.doi.org/10.1016/j.ajodo.2019.04.009>
10. Bucci R, Rongo R, Zunino B, Michelotti A, Bucci P, Alessandri-Bonetti G, et al. Effect of orthopedic and functional orthodontic treatment in children with obstructive sleep apnea: A systematic review and meta-analysis. *Sleep Med Rev* [Internet]. 2023;67(101730):101730. Disponible en: <http://dx.doi.org/10.1016/j.smrv.2022.101730>
11. Chaudhry U, Cohen JR, Al-Samawi Y. Use of cone beam computed tomography imaging for airway measurement to predict obstructive sleep apnea. *Cranio* [Internet]. 2020;40(5):418–24. Available from: <https://www.tandfonline.com/doi/full/10.1080/08869634.2020.1765602>
12. Cistulli PA, Palmisano RG, Poole MD. Treatment of obstructive sleep apnea syndrome by rapid maxillary expansion. *Sleep* [Internet]. 1998;21(8):831–5. Available from: <https://pubmed.ncbi.nlm.nih.gov/9871945/>
13. Fernández J, Pérez T, Rocío M, Pellicer V, Rodríguez E, Jaime M. Impact of an Oral Appliance on Obstructive Sleep Apnea Severity, Quality of life, and Biomarkers. Case-control study. The American Laryngological, Rhinological and Otological Society. [Internet]. 2017. Disponible en: <https://doi.org/10.1002/lary.26913>
14. Filho E, Araujo T, Neto J, Borges N, Neto B, Campelo V, et al. Correlation of cephalometric and anthropometric measures with obstructive sleep apnea severity. *International Archives of Otorhinolaryngology* [Internet]. 2014;17(03):321–8. Available from: https://www.ncbi.nlm.nih.gov/translate.goog/pmc/articles/PMC4423249/?x_tr_sl=en&x_tr_tl=es&x_tr_hl=es&x_tr_pt_Q=SC
15. Francis CE, Quinell T. Mandibular Advancement Devices for OSA: an alternative to CPAP? Pulmonary Therapy. 2020. <https://doi.org/10.1007/s41030-020-00137-2>
16. Giuca MR, Carli E, Lardani L, Pasini M, Miceli M, Fambrini E. Pediatric obstructive sleep apnea syndrome: Emerging evidence and treatment approach. *ScientificWorldJournal* [Internet]. 2021;2021:5591251. Disponible en: <http://dx.doi.org/10.1155/2021/5591251>
17. Garg RK, Afifi AM, Garland CB, Sanchez R, Mount DL. Pediatric Obstructive Sleep Apnea: Consensus, controversy, and craniofacial Considerations. *Plastic and Reconstructive Surgery/PSEF CD Journals* [Internet]. 2017;140(5):987–97. Available from: <https://pubmed.ncbi.nlm.nih.gov/29068938/>
18. Haddaway NR, Page MJ, Pritchard CC, McGuinness LA. PRISMA2020: un paquete R y una aplicación Shiny para producir diagramas de flujo compatibles con PRISMA 2020, con interactividad para una transparencia digital optimizada y Open Synthesis Campbell Systematic Reviews. 2022;18:e1230. <https://doi.org/10.1002/cl2.1230>

RECISATEC – REVISTA CIENTÍFICA SAÚDE E TECNOLOGIA ISSN 2763-8405

ORTHODONTICS AND ITS IMPACT ON SLEEP QUALITY CAUSED BY OBSTRUCTIVE APNEA
Yanderin Nicole Apolo Carrión, Carla Jessenia Rodríguez Robles, Nancy Pilar Sauca Chalán, Mateo Eduardo Ordóñez Nieto,
María Yolanda Yunga Picón, Mónica Beatriz Dávila Arcentales, Milton Fabricio Lafebre Carrasco

19. Hamoda MM, Kohzuka Y, Almeida FR. Oral appliances for the management of OSA. Chest [Internet]. 2018;153(2):544–53. Available from: <https://pubmed.ncbi.nlm.nih.gov/28624182/>
20. Hermida L, Restrepo C, Bruxismo del Sueño y Síndrome de Apnea Obstruktiva del Sueño en Niños: Revisión Narrativa. Asociación Latinoamericana de Odontopediatría [Internet]. 2016;6(2):99-105. Disponible en: <https://doi.org/10.47990/alop.v6i2.118>
21. Hidalgo BME, Fuchslocher KG, Vargas IM, Palacios FMJ. Rol del ortodoncista en ronquidos y apneas obstructivas. Revista Médica Clínica Las Condes [Internet]. 2013;24(3):501–9. Available from: <https://www.sciencedirect.com/science/article/pii/S0716864013701871>
22. Hidalgo-Martínez P, Lobelo R. Epidemiología mundial, latinoamericana y colombiana y mortalidad del síndrome de apnea-hipopnea obstructiva del sueño (SAHOS). Rev Fac Med Univ Nac Colomb [Internet]. 2017;65(1Sup):17–20. Disponible en: <http://dx.doi.org/10.15446/revfacmed.v65n1sup.59565>
23. Lorenzi Poluha R, Ávila Baena Stefaneli E, Hissashi Terada H. A Odontologia na síndrome da apneia obstrutiva do sono: diagnóstico e tratamento. Revista brasileira de Odontologia. [Internet]. 2015. Available from: [A Odontologia na síndrome da apneia obstrutiva do sono: diagnóstico e tratamento \(bvsalud.org\)](http://bvsalud.org)
24. Mediano O, Mangado NG, Montserrat JM, Alonso-Álvarez ML, Almendros I, Alonso-Fernández A, et al. Documento internacional de consenso sobre apnea obstructiva del sueño. Archivos De Bronconeumología 2022 [Internet]. 2022;58(1):52–68. Available from: <https://archbronconeumol.org/es-documento-internacional-consenso-sobre-apnea-articulo-S0300289621001150?codref=B5z2BnxFPcS9G9rDdbXamCUJ9ACqNYrEurZfqeL4PZKWP2fy5DL SuhzBSAWGn4tjifNwRmq5r>
25. Meltzer LJ, Mindell JA. Sleep and sleep disorders in children and adolescents. Psychiatr Clin North Am [Internet]. 2006;29(4):1059–76. Disponible en: <http://dx.doi.org/10.1016/j.psc.2006.08.004>
26. Momany SM, AlJamal G, Shugaa-Addin B, Khader YS. Cone Beam Computed tomography analysis of upper airway measurements in patients with obstructive sleep apnea. The American Journal of the Medical Sciences [Internet]. 2016;352(4):376–84. Available from: <https://doi.org/10.1016/j.amjms.2016.07.014>
27. Pattipati M, Gudavalli G, Zin M, Dhulipalla L, Kolack E, Karki M, et al. Continuous Positive Airway Pressure vs Mandibular Advancement Devices in the Treatment of Obstructive Sleep Apnea: An Updated Systematic Review and Meta-Analysis. Curēus [Internet]. 2022; Available from: <https://pubmed.ncbi.nlm.nih.gov/35251830/>
28. Roncero A, Castro S, Herrero J, Romero S, Caballero C, Rodríguez P. Obstructive sleep apnea [Internet]. U.S. National Library of Medicine; 2022. Available from: <https://www.ncbi.nlm.nih.gov/pmc/articles/PMC10369596/>
29. Sánchez-Ariza CA. Tratamiento con dispositivos orales para síndrome de apnea-hipopnea obstructiva del sueño (SAHOS). Revista de la Facultad de Medicina 2017 [Internet]. 2017;65(1Sup):121-8. Disponible en: http://www.scielo.org.co/scielo.php?script=sci_arttext&pid=S0120-00112017000500121
30. Savoldi F, Dagassan-Berndt D, Patcas R, Mak WS, Kanavakis G, Verna C, et al. The use of CBCT in orthodontics with special focus on upper airway analysis in patients with sleep-disordered breathing. Dento-maxillo-facial Radiology/Dentomaxillofacial Radiology [Internet]. 2024; Available from: <https://academic.oup.com/dmfr/article/53/3/178/7587517?login=false>



RECISATEC – REVISTA CIENTÍFICA SAÚDE E TECNOLOGIA
ISSN 2763-8405

ORTHODONTICS AND ITS IMPACT ON SLEEP QUALITY CAUSED BY OBSTRUCTIVE APNEA
Yanderin Nicole Apolo Carrión, Carla Jessenia Rodríguez Robles, Nancy Pilar Sauca Chalán, Mateo Eduardo Ordóñez Nieto,
María Yolanda Yunga Picón, Mónica Beatriz Dávila Arcentales, Milton Fabricio Lafebre Carrasco

31. Soori R, Baikunje N, D'sa I, Bhushan N, Nagabhushana B, Hosmane GB. Pitfalls of AHI system of severity grading in obstructive sleep apnoea. *Sleep Science* [Internet]. 2022;15(S 01):285–8. Available from: <https://www.ncbi.nlm.nih.gov/pmc/articles/PMC8889969/>
32. Wojda M, Kostrzewa-Janicka J, Śliwiński P, Bieleń P, Jurkowski P, Wojda R, et al. Mandibular advancement devices in obstructive sleep apnea patients intolerant to continuous positive airway pressure treatment. In: *Advances in experimental medicine and biology* [Internet]. 2018. p. 35–42. Available from: <https://pubmed.ncbi.nlm.nih.gov/30255301/>