

**VOLUMETRIC ANALYSIS OF THE OROPHARYNX ACCORDING TO CRANIOFACIAL MORPHOLOGY USING CBCT IN SEVENTH-CYCLE STUDENTS AT THE FACULTY OF DENTISTRY, UNIVERSITY OF CUENCA****ANÁLISE VOLUMÉTRICA DA OROFARINGE DE ACORDO COM A MORFOLOGIA CRANIOFACIAL POR MEIO DE CBCT EM ALUNOS DO SÉTIMO CICLO DA FACULDADE DE ODONTOLOGIA DA UNIVERSIDADE DE CUENCA****ANÁLISIS VOLUMÉTRICO DE LA OROFARINGE SEGÚN LA MORFOLOGÍA CRANEOFACIAL MEDIANTE CBCT EN ALUMNOS DE SÉPTIMO CICLO DE LA FACULTAD DE ODONTOLOGÍA DE LA UNIVERSIDAD DE CUENCA**

Manuel Estuardo Bravo Calderon¹, Lissbeth Lazo Santacruz², Geovanny Matias Quizhpi Zatisaval², Edisson Ojeda², Anderson Steve Soto Santiana²

e41334

<https://doi.org/10.47820/recisatec.v4i1.334>

RECEIVED: 12/08/2023

APPROVED: 01/08/2024

PUBLISHED: 01/22/2024

ABSTRACT

Objective: To conduct a volumetric analysis of the oropharynx using cone beam computed tomography scans in seventh-cycle dental students with diverse facial biotypes and skeletal patterns. **Methods:** The tomographic sample was obtained from a group of 34 seventh-cycle students from the Faculty of Dentistry, whose age range is from 20 to 30 years. The tomographic samples were obtained through an imaging center in the city of Cuenca. **Results:** No significant difference was evidenced between the oropharyngeal volume and the facial biotype, similarly, there was no difference between the oropharyngeal volume and the skeletal pattern. The results obtained were that the lowest volume was skeletal class II and in the mesofacial biotype and, on the contrary, a greater volume was found in class I and in the brachyfacial biotype. **Conclusions:** CBCT today is an imaging method of great importance in the field of dentistry. This study allowed us to identify that there is no significant difference in the oropharyngeal airway volume with respect to the facial biotype. According to the skeletal class, there may be an increase or decrease in the oropharyngeal airway volume.

KEYWORDS: Oropharynx. Angle Classification. Malocclusions. Cone Beam Computed Tomography.

RESUMO

Objetivo: Realizar uma análise volumétrica da orofaringe por meio de tomografias computadorizadas de feixe cônico em estudantes do sétimo ciclo da faculdade de odontologia com diversos biotipos faciais e padrões esqueléticos. **Métodos:** A amostra tomográfica foi obtida de um grupo de 34 estudantes do sétimo ciclo da Faculdade de Odontologia, cuja faixa etária varia de 20 a 30 anos. As amostras tomográficas foram obtidas por meio de um centro de imagem na cidade de Cuenca. **Resultados:** Não foi evidenciada diferença significativa entre o volume orofaríngeo e o biotipo facial, da mesma forma, não existiu diferença entre o volume orofaríngeo e o padrão esquelético. Obteve-se como resultados que o volume mais baixo foi a classe esquelética II e no biotipo mesofacial e, pelo contrário, encontrou-se um maior volume na classe I e no biotipo braquifacial. **Conclusões:** A CBCT, hoje, é um método de imagem de grande importância no campo da odontologia. Este estudo permitiu-nos identificar que não há diferença significativa no volume da via aérea orofaríngea em relação ao biótipo facial. De acordo com a classe esquelética, pode haver um aumento ou diminuição no volume da via aérea orofaríngea.

PALAVRAS-CHAVE: Orofaringe. Classificação de Angle, Más Oclusões. Tomografia Computadorizada de Feixe Cônico.

RESUMEN

Objetivo. Realizar un análisis del volumen de la orofaringe por medio de tomografías computadorizadas de haz cónico de estudiantes de séptimo ciclo de la facultad de odontología con diversos biotipos

¹ Orthodontist, Department of Orthodontics, School of Dentistry, University of Cuenca – Ecuador.

² Students of the Faculty of Dentistry of the University of Cuenca, Cuenca – Ecuador.



RECISATEC – REVISTA CIENTÍFICA SAÚDE E TECNOLOGIA ISSN 2763-8405

VOLUMETRIC ANALYSIS OF THE OROPHARYNX ACCORDING TO CRANIOFACIAL MORPHOLOGY USING CBCT IN SEVENTH-CYCLE STUDENTS AT THE FACULTY OF DENTISTRY, UNIVERSITY OF CUENCA
Manuel Estuardo Bravo Calderon, Lissbeth Lazo Santacruz, Geovanny Matias Quizhpi Zatisaval, Edisson Ojeda, Anderson Steve Soto Santiana

faciales y patrones esqueléticos. Métodos. Se obtuvo la muestra tomográfica de un grupo de 34 estudiantes de la Facultad de Odontología, de séptimo ciclo, cuyo rango de edad va de 20 a 30 años. Las muestras tomográficas fueron obtenidas por medio de un centro imagenológico de la ciudad de Cuenca. Resultados. No se evidenció diferencia significativa entre el volumen orofaríngeo y el biotipo facial, de igual manera, no existió diferencia entre el volumen orofaríngeo y el patrón esquelético. Se obtuvo como resultados que el volumen más bajo fue la clase esquelética II y en el biotipo mesofacial y, por el contrario, se encontró un mayor volumen en la clase I y en el biotipo braquifacial. Conclusiones. La CBCT hoy en día es un método imagenológico de gran importancia dentro del campo odontológico, en el cual dentro de estudio permitió identificar que no existe diferencia significativa del volumen orofaríngeo con respecto al biotipo facial y que de acuerdo con la clase esquelética puede existir un aumento o disminución del mismo.

PALABRAS CLAVE: Orofaringe. Clasificación de Angle, Maloclusiones. Tomografía Computarizada de Haz Cónico.

INTRODUCTION

Over the years, technology has been having a great apogee worldwide and especially in health science areas. In the dental field, after the appearance of cone beam computed tomography (CBCT), there has been a wide acceptance, especially in the orthodontic area, because CBCT allows obtaining three-dimensional images of an area of interest to be studied. A clear example can be seen in the exploration of the airway and its relationship with craniofacial development, which has attracted the attention of different disciplines such as otorhinolaryngology, phonoaudiology, pediatrics and dentistry. Among the techniques used to evaluate the airway are rhinoendoscopy, rhinomanometry, clinical rhinomanometry, cephalometry, computed tomography (CT), nuclear magnetic resonance and cone beam computed tomography (CBCT). Clinical evaluation of changes or alterations in the upper airway at the beginning of orthodontic treatment is essential. ¹

The main advantage of cone beam tomography (CBCT) over 2D radiographs lies in its ability to provide three dimensional volumetric, surface and cross-sectional information about craniofacial structures. ¹ This advance has allowed orthodontists and researchers to overcome the significant limitations associated with 2D radiographs, such as magnification, geometric distortion, overlapping structures and variability in head position. Likewise, in the initial stages of CBCT integration in the orthodontic setting, there was a propensity to convert the three-dimensional data set into a 2D image, making possible the manipulation of images in multiple planes, longitudinal and volumetric measurement of structures. ²

Through CBCT, nowadays it allows the adequate diagnosis of oropharyngeal alterations such as: tonsillar hypertrophy that can manifest itself as an increase of the oropharyngeal space or its decrease related to Obstructive Sleep Apnea Syndrome. ³

Therefore, the purpose of this study is to evaluate the volume of the oropharynx in university students, with different facial biotypes, by means of cephalometric images obtained from CBCT, as well as the determination of the oropharyngeal volume from the skeletal pattern by means of the ANB angle



RECISATEC – REVISTA CIENTÍFICA SAÚDE E TECNOLOGIA ISSN 2763-8405

VOLUMETRIC ANALYSIS OF THE OROPHARYNX ACCORDING TO CRANIOFACIAL MORPHOLOGY USING CBCT IN SEVENTH-CYCLE STUDENTS AT THE FACULTY OF DENTISTRY, UNIVERSITY OF CUENCA
Manuel Estuardo Bravo Calderon, Lissbeth Lazo Santacruz, Geovanny Matias Quizhpi Zatisaval, Edisson Ojeda, Anderson Steve Soto Santiana

and gender, since by means of the craniofacial morphology the different factors that can influence growth and development can be evidenced.

THEORETICAL BASIS

Skeletal pattern

The skeletal pattern refers to the existing anteroposterior relationship between the maxilla and mandible in relation to the base of the skull; it is said that this relationship can have both forward and backward positions. Likewise, the skeletal pattern of Steiner and Ricketts, who emphasize the relationship between the anterior skull base and the maxillary position. ³

Skeletal classes ⁴

- **Class I:** biprotrusive relationship of the jaws, whose ANB angle varies between 0 and 4 degrees.
- **Class II:** this skeletal pattern is given by a protrusion at the maxillary level and a normoposition or retrusion at the mandibular level.
- **Class III:** maxillary normoposition or retrusion and mandibular protrusion or normoposition. The ANB angle is less than 0 degrees.

Facial analysis, pattern and biotype ⁴

The skeletal pattern refers to the existing anteroposterior relationship between the maxilla and mandible in relation to the base of the skull; it is said that this relationship can have both forward and backward positions. Likewise, the skeletal pattern of Steiner and Ricketts, who emphasize the relationship between the anterior skull base and the maxillary position. ³

Skeletal classes ⁴

- **Class I:** biprotrusive relationship of the jaws, whose ANB angle varies between 0 and 4 degrees.
- **Class II:** this skeletal pattern is given by a protrusion at the maxillary level and a normoposition or retrusion at the mandibular level.
- **Class III:** maxillary normoposition or retrusion and mandibular protrusion or normoposition. The ANB angle is less than 0 degrees.

Facial analysis, pattern and biotype ⁴

In the orthodontic area, facial analysis is fundamental for a proper diagnosis of the appearance of the face; therefore, by means of a cranial index, an anteroposterior and transversal analysis has been allowed, thus allowing a proper diagnosis and differentiation of the different facial types such as: brachyfacial, mesofacial or dolichofacial.

- **Dolichofacial:** patients have a long and narrow face, whose profile is convex and in which dental crowding is usual.
- **Mesofacial:** harmony of both vertical and transverse diameters is evident.



RECISATEC – REVISTA CIENTÍFICA SAÚDE E TECNOLOGIA ISSN 2763-8405

VOLUMETRIC ANALYSIS OF THE OROPHARYNX ACCORDING TO CRANIOFACIAL MORPHOLOGY USING CBCT IN SEVENTH-CYCLE STUDENTS AT THE FACULTY OF DENTISTRY, UNIVERSITY OF CUENCA
Manuel Estuardo Bravo Calderon, Lissbeth Lazo Santacruz, Geovanny Matias Quizhpi Zatisaval, Edisson Ojeda, Anderson Steve Soto Santiana

- **Brachyfacial:** patients with a short and wide face, whose dental arches are wider than the other facial types.

On the other hand, by means of cephalometric radiographs in conjunction with age and sex, it allows the identification of a basic facial scheme of the patients, thus allowing the orthodontic treatment to be adequate.³

RESPIRATORY SYSTEM

The respiratory system plays a fundamental role in the life of human beings since it is responsible for gas exchange, thus allowing the transport of oxygen to the lungs, showing that the air sent is filtered, moistened and heated by the mucous areas found at the level of the nasal cavity, paranasal sinuses, pharynx, larynx, trachea and especially at the level of the bronchi. For this reason, it should be taken into account that the oropharynx is part of the three fundamental components of the pharyngeal airway, which together with the nasopharynx play an important role in terms of breathing and swallowing that is carried out by human beings.⁴

METHODOLOGY

This is a descriptive study, which involved the collection of 34 cephalometric images from CBCT of students of the Seventh Cycle School of Dentistry during the academic period September 2023 - February 2024. The tomographies were acquired in an imaging center in the city of Cuenca; whose field of vision was wide, allowing the visualization of the complete skull.

Study sample: The primary sample was made up of students with an age range between 20 and 30 years old. McNamara's analysis was taken as a reference, in which the evaluation of the airway was based on the posterior contour of the soft palate to the posterior pharyngeal wall and the lower edge of the mandible to the posterior pharyngeal wall. Among the exclusion criteria, CT scans of patients with oropharyngeal airway obstruction and who had undergone orthognathic surgery were rejected. The final and definitive sampling consisted of 34 CT scans of 24 women and 10 men, who were divided into different groups according to sex, facial biotype and skeletal pattern.

Cephalometric analysis: a database was created with the lateral radiographs of each student, then the cephalometric points were traced (Image 1) through the NemoCeph software, any type of irregularity or point that according to the student's criteria was out of position was modified. Emphasis was placed on the following angles: facial axis, facial depth, mandibular plane angle, lower facial height, mandibular arch and ANB.

Vert's index was calculated from the planes and angles for their respective cephalometric analysis (Table 1) to determine the facial biotype and the ANB angle to determine the skeletal pattern.

RECISATEC – REVISTA CIENTÍFICA SAÚDE E TECNOLOGIA
ISSN 2763-8405

VOLUMETRIC ANALYSIS OF THE OROPHARYNX ACCORDING TO CRANIOFACIAL MORPHOLOGY USING CBCT IN SEVENTH-CYCLE STUDENTS AT THE FACULTY OF DENTISTRY, UNIVERSITY OF CUENCA
Manuel Estuardo Bravo Calderon, Lissbeth Lazo Santacruz, Geovanny Matias Quizhpi Zatisaval, Edisson Ojeda, Anderson Steve Soto Santiana

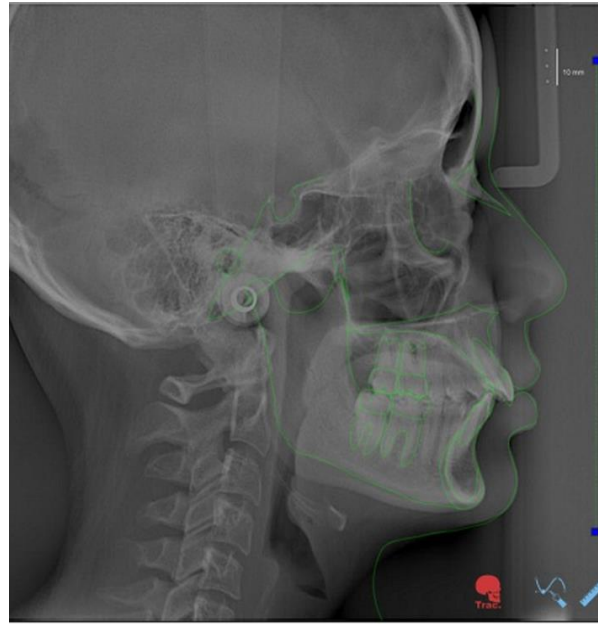


Image 1

Table 1: Cephalometric planes and angles used

Angles	Definition
Facial axis	Ba-Na and Pt-Gn plane
Facial depth	N-Gn and Po-Or plane
Mandibular plane angle	Po-Or and Go-Me plane
Lower facial height	Xi-ENA line with andibular body axis
Mandibular arch	Condilar shaft with distal extensión
ANB	N-A and N-B plane

Taken from: Gregoret and Zamora-Montes de Oca.

Oropharyngeal volume: The size of the pharyngeal cavity was assessed by adjusting the position of the head to ensure uniformity and accuracy of the procedure. The sagittal and coronal views were aligned by adjusting specific points to form the Frankfurt horizontal plane (FH). El and Palomo parameters were used to define the superior, inferior, anterior and posterior regions of the pharynx and its lateral borders.

Once the oropharyngeal tract has been delineated, the three-dimensional development is measured and the volume in cm³ is calculated. Statistical analysis allows the examination of variables related to facial biotype, skeletal structure, sex and their associations with oropharyngeal volume.

RECISATEC – REVISTA CIENTÍFICA SAÚDE E TECNOLOGIA
ISSN 2763-8405

VOLUMETRIC ANALYSIS OF THE OROPHARYNX ACCORDING TO CRANIOFACIAL MORPHOLOGY USING CBCT IN SEVENTH-CYCLE STUDENTS AT THE FACULTY OF DENTISTRY, UNIVERSITY OF CUENCA
Manuel Estuardo Bravo Calderon, Lissbeth Lazo Santacruz, Geovanny Matias Quizhpi Zatisaval, Edisson Ojeda, Anderson Steve Soto Santiana

The statistical analysis was performed using the IBM SPSS Statistics 27 program; which through this allowed the evaluation of the facial biotype as well as the sex of the participants in said study; likewise, the skeletal pattern and occlusal class were based on the Ricketts and Vert analytical tests; finally, the Spearman correlation was carried out to identify the relationship between the oropharyngeal volume and the angles in Table 1.

RESULTS

Of the 34 tomographies collected, it was evidenced that 24 of these belong to the masculine sex and 10 to the feminine sex. In addition, a distribution of these was made according to the facial biotype and skeletal pattern. Such data, synthesized in (Table 2), can be observed.

Table 2: Distribution of CBCT according to gender, facial biotype and skeletal pattern

Variables		n	(%)
Sex	Male	24	70,59%
	Female	10	29,41%
Facial biotype	Dolicofacial	10	29,41%
	Mesofacial	18	52,94%
	Brachyfacial	6	17,64%
Skeletal pattern	Class I	27	79,41%
	Class II	7	20,58%
	Class III	0	0%

Based on this, the highest oropharyngeal volume was obtained in individuals with brachyfacial biotype with 10.56 cm³, while the lowest volume was evidenced in mesofacial patients with 6.83 cm³ (Table 3).

Table 3: Oropharyngeal volume according to facial biotype

	N	x(cm ³)	min	Max
Dolicofacial	10	8,54 cm ³	6,3 cm ³	11,2 cm ³
Mesofacial	18	6,83 cm ³	6,16 cm ³	8,63 cm ³



RECISATEC – REVISTA CIENTÍFICA SAÚDE E TECNOLOGIA

ISSN 2763-8405

VOLUMETRIC ANALYSIS OF THE OROPHARYNX ACCORDING TO CRANIOFACIAL MORPHOLOGY USING CBCT IN SEVENTH-CYCLE STUDENTS AT THE FACULTY OF DENTISTRY, UNIVERSITY OF CUENCA
Manuel Estuardo Bravo Calderon, Lissbeth Lazo Santacruz, Geovanny Matias Quizhpi Zatisaval, Edisson Ojeda, Anderson Steve Soto Santiana

Brachyfacial	6	10,56 cm ³	8,3 cm ³	11,81 cm ³
--------------	---	-----------------------	---------------------	-----------------------

In the same way the tomographies showed that those with class I pattern have the highest VO and those with class II represent a lower value, however, no patients with class III pattern were found, therefore, there is no significant difference for biotype and skeletal pattern.

The average value of VO in men is 9.16 cm³ and for women it is 8.07 cm³, it can be said that there is a great difference between the two sexes.

DISCUSSION

Within the orthodontic area, the study of the respiratory tract and craniofacial development has made it possible to reveal certain alterations at the level of the oropharynx that in certain cases can lead to changes in growth and dentofacial development, generating malocclusions and alterations at the facial level.

Moss's functional matrix theory suggests that craniofacial development is primarily influenced by the activity of the surrounding soft tissues. This interaction between the pharyngeal airways and the craniofacial structures means that irregularities in these airways can influence the position of the surrounding skeleton.

The use of a CBCT scan to measure the oropharyngeal airway and evaluate its morphology in 3D is more accurate than other radiological methods. In this study, we performed angle measurements using a CBCT-derived virtual cephalogram and concluded that it is suitable for cephalometric analysis with accuracy comparable to that of a physical cephalogram.

This study found no significant differences between sex and airway volume. This is due to the size and distribution of the samples used. However, in comparison to an article published in 2020, it can be observed that the most frequent facial biotype in that one was brachyfacial compared to this study being drafted, which is mesofacial unlike the 2020 article where this biotype is the least frequent. Similarly, regarding the oropharyngeal volume, in this study brachyfacial patients had the largest volume while in the comparative article it was the mesofacial biotype that presented it.³

The literature mentions that the pharyngeal structure continues to grow until the age of 13 years, after which the incubation period continues until the age of 18 years. Between the ages of 20 and 50, the soft palate expands and increases in thickness, while the pharyngeal region narrows and lengthens.

The aim of this study was to compare airway volume between different facial types and skeletal patterns by CBCT. CBCT is of great importance for the diagnosis of OSA associated with type II and is essential for orthodontic and orthognathic surgery treatment planning. However, the main limitation was the limited number of CBCT images available, which may have influenced the statistical significance of the observed volume differences.



RECISATEC – REVISTA CIENTÍFICA SAÚDE E TECNOLOGIA

ISSN 2763-8405

VOLUMETRIC ANALYSIS OF THE OROPHARYNX ACCORDING TO CRANIOFACIAL MORPHOLOGY USING CBCT IN SEVENTH-CYCLE STUDENTS AT THE FACULTY OF DENTISTRY, UNIVERSITY OF CUENCA
Manuel Estuardo Bravo Calderon, Lissbeth Lazo Santacruz, Geovanny Matias Quizhpi Zatisaval,
Edisson Ojeda, Anderson Steve Soto Santiana

CONCLUSIONS

By means of this study, it could be evidenced that obtaining cephalometric images from CBCT are favorable, since they allow the proper diagnosis of certain pathologies or alterations that may occur at the level of the oropharynx, either showing its increase or decrease in volume respectively. In addition, it can be evidenced that the oropharyngeal volume usually varies depending on the facial biotype as well as the skeletal pattern. The individuals who presented less volume were class II, however, at the level of facial biotype analysis, no significant variation was obtained.

REFERENCES

1. Claver-del Valle F, Palma-Díaz E, Hidalgo-Rivas A. Guías de uso de tomografía computarizada de haz cónico en ortodoncia: revisión narrativa. *Av Odontoestomatol.* [Internet]. 2022 Dic;38(4):169-178. Disponible en: http://scielo.isciii.es/scielo.php?script=sci_arttext&pid=S0213-12852022000400007&lng=es. Epub 06-Feb-2023. <https://dx.doi.org/10.4321/s0213-12852022000400007>.
2. Fernández DAG, Gutiérrez RR, Rosales ES, Peña RD. Caracterización de la vía aérea faríngea en pacientes clase II en relación con el patrón facial esquelético. *Revista mexicana de ortodoncia.* 2016;4(4):227–233. <https://doi.org/10.1016/j.rmo.2017.03.004>
3. Huamaní Guzman HM, Soldevilla Galarza L, Aliaga-Del Castillo A. Análisis volumétrico de la orofaringe según la morfología craneofacial mediante la tomografía cone beam. *Odontol Sanmarquina* [Internet]. 13 nov 2020;23(4):385-92. Disponible en: <https://revistasinvestigacion.unmsm.edu.pe/index.php/odont/article/view/19100>
4. Guzman HMH. Volumen de la vía orofaríngea según el biotipo facial en tomografías cone beam de pacientes que acudieron al Instituto de Diagnóstico Maxilofacial [Internet]. Core.ac.uk. 2016. Disponible en: <https://core.ac.uk/download/pdf/323343934.pdf>