



RECISATEC – REVISTA CIENTÍFICA SAÚDE E TECNOLOGIA
ISSN 2763-8405

EVALUATION OF THE CONDYLAR POSITION IN RELATION TO THE DIFFERENT MALOCCLUSIONS OF A STUDENT POPULATION

AVALIAÇÃO DA POSIÇÃO CONDILAR EM RELAÇÃO ÀS DIFERENTES MALCLUSÕES DE UMA POPULAÇÃO DE ESTUDANTES

EVALUACIÓN DE LA POSICIÓN CONDILAR EN RELACIÓN A LAS DIFERENTES MALOCCLUSIONES DE UNA POBLACIÓN ESTUDIANTIL

Manuel Estuardo Bravo Calderón¹, Paula Lisseth Alberca Agreda², Monica Catalina Arias Astudillo¹, Diana Karolina Bustamante Granda¹, Nayeli Maldonado Alulima¹

e41340

<https://doi.org/10.47820/recisatec.v4i1.340>

RECEIVED: 12/08/2023

APPROVED: 01/08/2024

PUBLISHED: 01/22/2024

ABSTRACT

Studying the position of the condyle in the glenoid cavity is an important aspect of achieving the diagnosis and the treatment plan in dentistry. The posterior position of the condyle in the glenoid cavity is not a completely reliable predictor of the lack or appearance of disc displacement, although they are related (1). The TMJ is a small joint with a complex morphology surrounded by bony tissues that create a superimposition of images, especially in the petrous region of the temporal bone, the mastoid process and the articular eminence (1). Studies on the ideal position of the condyles have shown that the healthiest condyle-fossa relationship in which the condyle is centered anteriorly in the mandibular fossa. The following research aims to evaluate the condylar position in relation to different malocclusions of thirty-two students of the Faculty of Dentistry of the University of Cuenca. The research has a quantitative approach, carried out by means of numerical analysis. The population used was thirty-two students from the Faculty of Odontology in the University of Cuenca, aged between 21 and 29 years, who underwent cone beam computed tomography. The research was carried out as a descriptive retrospective sample and provides systematic information. The research used is of a primary source, using CBCT scans obtained from an image bank at the CERIOM Radiology Centre in the city of Cuenca, and the tomographic examination will be imported in DICOM format into the RadiAnt DICOM Viewer software (64-bit).

KEYWORDS: Malocclusions. Condylar position. Temporomandibular joint. Temporomandibular disorders. Molar classes.

RESUMO

O estudo da posição do côndilo na cavidade glenoidal é um aspeto crítico para a realização do diagnóstico ortodôntico e do plano de tratamento. A posição posterior do côndilo na cavidade glenoide não é um preditor totalmente confiável da ausência ou aparecimento de deslocamento do disco, embora estejam relacionados (1). A ATM é uma articulação pequena, de morfologia complexa, circundada por tecidos ósseos que criam uma sobreposição de imagens, principalmente na região petrosa do osso temporal, na glândula mamária e na eminência articular (1). Estudos sobre a posição ideal dos côndilos mostraram que a relação côndilo-fossa mais saudável é aquela em que o côndilo está centrado anteriormente na fossa mandibular. A presente investigação tem como objetivo avaliar a posição condilar em relação às diferentes má oclusões de trinta e dois alunos da Faculdade de Medicina Dentária da Universidade de Cuenca. A pesquisa tem uma abordagem quantitativa realizada por meio de análise numérica. A população utilizada foi de trinta e dois estudantes da Faculdade de Medicina Dentária da Universidade de Cuenca, com idades compreendidas entre os 21 e 29 anos, que foram submetidos a tomografia computadorizada de feixe cônico. A investigação foi realizada como uma amostra descritiva retrospectiva e fornece informações sistemáticas. A fonte de investigação utilizada é primária, utilizando exames de TCFC obtidos num banco de imagens do centro de radiologia

¹ Tutor - Faculty of Dentistry, University of Cuenca, PHD in Orthodontics, Chairman Postgraduate Orthodontics (Dentistry), Cuenca-Ecuador.

² Student at the Faculty of Dentistry, University of Cuenca, Cuenca - Ecuador.



RECISATEC – REVISTA CIENTÍFICA SAÚDE E TECNOLOGIA ISSN 2763-8405

EVALUATION OF THE CONDYLAR POSITION IN RELATION TO THE DIFFERENT MALOCCLUSIONS OF A STUDENT POPULATION
Manuel Estuardo Bravo Calderón, Paula Lisseth Alberca Agreda, Monica Catalina Arias Astudillo,
Diana Karolina Bustamante Granda, Nayeli Maldonado Alulima

CERIOM, na cidade de Cuenca, e o exame tomográfico será importado em formato DICOM para o software RadiAnt DICOM Viewer (64 bits).

PALAVRAS-CHAVE: Más oclusões. Posição condilar. Articulação temporomandibular. Disfunção temporomandibular. Classes molares.

RESUMEN

El estudio de la posición del cóndilo en la cavidad glenoidea es un aspecto crítico para el diagnóstico y el plan de tratamiento de la ortodoncia. La posición posterior del cóndilo en la cavidad glenoidea no es un predictor totalmente fiable de la ausencia o aparición de desplazamiento discal, aunque sí están relacionados (1). La ATM es una pequeña articulación de morfología compleja, rodeada de tejidos óseos que crean una superposición de imágenes, principalmente en la región petrosa del hueso temporal, en la glándula mamaria y en la eminencia articular (1). Los estudios sobre la posición óptima de los cóndilos han demostrado que la relación más saludable con la condilofosa es aquella en la que el cóndilo está centrado anteriormente en la fosa mandibular. La presente investigación tiene como objetivo evaluar la posición condilar en relación con las diferentes maloclusiones de treinta y dos estudiantes de la Facultad de Odontología de la Universidad de Cuenca. La investigación tiene un enfoque cuantitativo realizado a través del análisis numérico. La población utilizada fue de treinta y dos estudiantes de la Facultad de Odontología de la Universidad de Cuenca, con edades comprendidas entre los 21 y 29 años, a quienes se les realizó tomografía computarizada de haz cónico. La investigación se realizó como una muestra descriptiva retrospectiva y aporta información sistemática.

PALABRAS CLAVE: Maloclusiones. Posición condilar. Articulación temporomandibular. Trastornos temporomandibulares. Clases molares.

SPECIFIC GOALS

- To analyze the right and left articulation of each of the students by evaluating the condylar position.
- To determine the condylar position of the study population using the Frankfurt plane as a reference.

INTRODUCTION

The role of the optimal condylar position found in the glenoid cavity in the proper functioning of the stomatognathic system has been the focus of research and controversy throughout the history of dentistry.

Several studies have demonstrated a significant relationship between occlusal factors and joint morphology. However, it has also been reported that the posterior position of the condyle in the glenoid cavity is not a completely reliable predictor of the lack or appearance of disc displacement, despite the relationship between the two. Although in internal derangements the condyle tends to be displaced posteriorly in the glenoid cavity, in cases where the disc is displaced without reduction, the condyle is not as posteriorly displaced as in cases where the disc is displaced with reduction, i.e, in cases where the disc is displaced with reduction, the condyle is not as posteriorly displaced as in cases where the disc is displaced with reduction. This is when disc displacement is more severe, the posterior joint space tends to increase to the same distance as in a healthy joint with a normal condylar position. Kurita and cols (2) also found that when disc displacement becomes more severe, the condyle tends to return to



RECISATEC – REVISTA CIENTÍFICA SAÚDE E TECNOLOGIA ISSN 2763-8405

EVALUATION OF THE CONDYLAR POSITION IN RELATION TO THE DIFFERENT MALOCCLUSIONS OF A STUDENT POPULATION
Manuel Estuardo Bravo Calderón, Paula Lisseth Alberca Agreda, Monica Catalina Arias Astudillo,
Diana Karolina Bustamante Granda, Nayeli Maldonado Alulima

its more concentric position. Most studies on the position of the condyle in the glenoid cavity in asymptomatic patients with normal temporomandibular function were performed in patients with various deformities or non-ideal occlusion. Ikeda and Kawamura (3) evaluated the optimal condylar position in patients without disc displacement confirmed by MRI. By mounting in the articulator, ideal occlusion and adaptation of proportion and central occlusion is ensured.

Most of these pioneering studies used conventional radiographs, which are limited in their ability to accurately show the anatomical features of the TMJ. This is because the TMJ is a small joint with a complex morphology surrounded by bony tissues that create overlapping images, especially in the petrous region of the temporal bone, the mammary gland and the articular eminence (1).

Recently introduced in dentistry, 3D technology such as cone computed tomography (CBCT) allows a complete and reliable study of joint morphology and location with less ionizing radiation exposure and less costly, effective, non-invasive and quick comparison with traditional medical tomography. Linear measurements can be made with CBCT recordings in all three spatial planes, making it a method for imaging bony structures. There are several studies in the literature evaluating the accuracy and reliability of linear and angular measurements using CBCT. Measurements of the condyles are more accurate and reliable in CBCT than those obtained in panoramic projection. Studies on the ideal position of the condyles have shown that the healthiest condyle-fossa relationship is one in which the condyle is centered anteriorly in the mandibular fossa. Most of these studies were performed at a time when CT scans were not yet available. Furthermore, there was no specific analysis of the relationship between the variables symptoms, occlusion and condyle location (1).

The overall aim of this study is to evaluate condylar position and condyle-fossa relation in an asymptomatic population with type I, type II deformities and normal temporomandibular function using cone beam computed tomography.

METHODOLOGY

The nature of this research has a quantitative approach as it will be carried out by means of numerical analysis. The population used for the study was of thirty-two students from the Faculty of Dentistry at the University of Cuenca, between 21 and 29 years of age, who underwent cone beam computed tomography (CBCT). The research will be descriptive. Therefore, it offers systematic information, based on the organized description of the facts studied. The research source of the study will be primary because the information will be collected directly, by means of CBCT acquired from a device, the tomographic examination will be imported in DICOM format, to the RadiAnt DICOM Viewer software (64-bit) to calculate the linear measurements of the condyle fossa relation.

The right and left joint of each student was analyzed and the linear distances from the mandibular condyle to the glenoid cavity were measured. The slices in the tomographies of the 32 students from the dental school at the University of Cuenca were analyzed.



RECISATEC – REVISTA CIENTÍFICA SAÚDE E TECNOLOGIA ISSN 2763-8405

EVALUATION OF THE CONDYLAR POSITION IN RELATION TO THE DIFFERENT MALOCCLUSIONS OF A STUDENT POPULATION
Manuel Estuardo Bravo Calderón, Paula Lisseth Alberca Agreda, Monica Catalina Arias Astudillo,
Diana Karolina Bustamante Granda, Nayeli Maldonado Alulima

DETERMINATION OF CONDYLAR POSITION

Linear measurements of the position of the condyle in the articular cavity in the sagittal plane were performed with tomographic slices using points and planes presented (Figure 1). The CBCT of each subject was oriented according to the Frankfort plane and this line was used as a horizontal reference. In the axial view, the section showing the largest dimension of the condylar head was selected (Figure 2). Sagittal images oriented to the Frankfort plane were then reconstructed at a thickness of 1 mm and the two halves were selected.

The position of the condyle in the glenoid cavity was measured in sagittal slices. Since the measurements were taken in two central sections of the sagittal view, the average of these measurements represents the final values of the joint space. A true horizontal line was drawn at the superior point of the glenoid fossa and a superior reference point (FS) was obtained at the intersection of that line with the deepest point of the glenoid fossa. The most prominent points on the anterior (AC), posterior (PC) and superior (SC) sides of the articular head were defined sequentially. Finally, the tangential distance of the CA, CP and CS points of the glenoid fossa, representing the anterior (EAA), posterior (EAP) and superior (EAS) points, respectively, was measured. The EAP/EAA and EAS/EAA ratios were used to determine the location of the condyle in the alveolus (1).

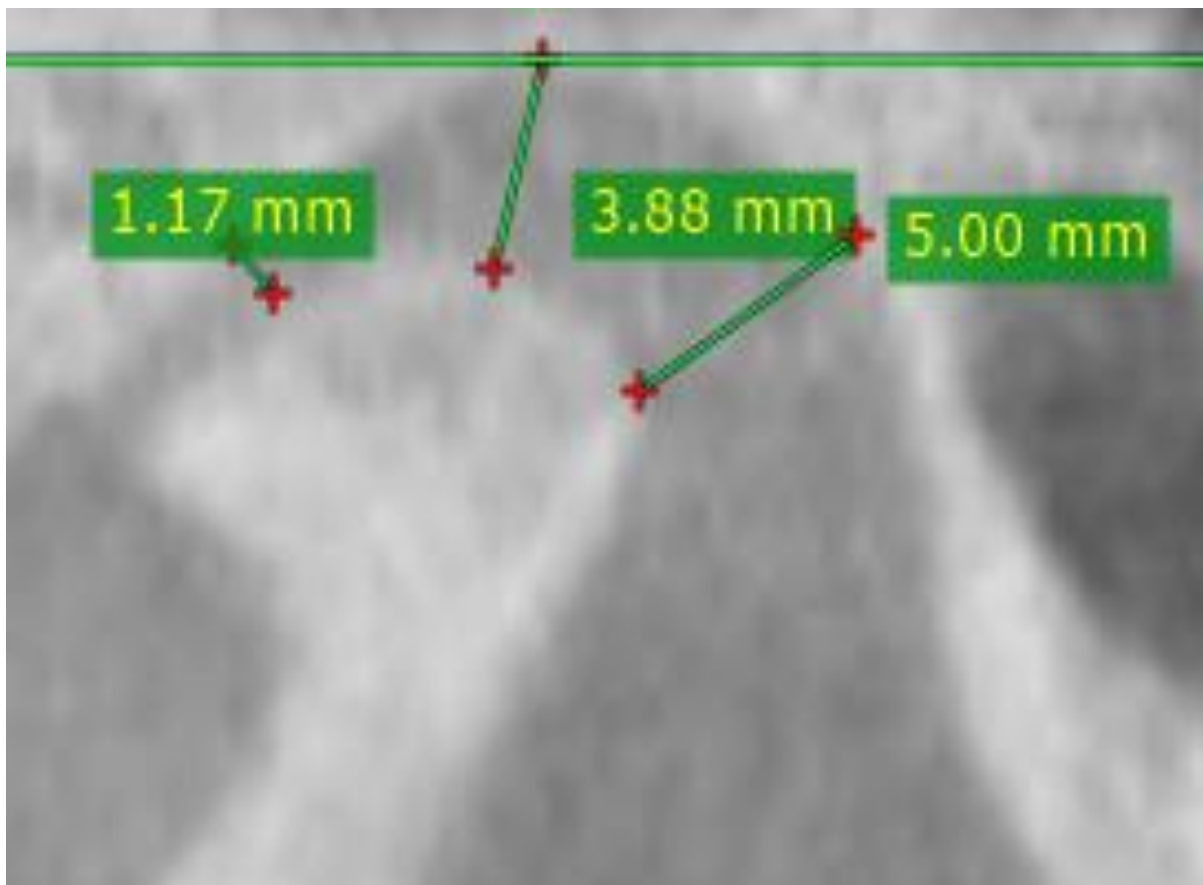


Figure 1: Linear measurements of the position of the condyle in the joint cavity according to the criteria of Ikeda and Kawamura



RECISATEC – REVISTA CIENTÍFICA SAÚDE E TECNOLOGIA

ISSN 2763-8405

EVALUATION OF THE CONDYLAR POSITION IN RELATION TO THE DIFFERENT MALOCCLUSIONS OF A STUDENT POPULATION
Manuel Estuardo Bravo Calderón, Paula Lisseth Alberca Agreda, Monica Catalina Arias Astudillo,
Diana Karolina Bustamante Granda, Nayeli Maldonado Alulima

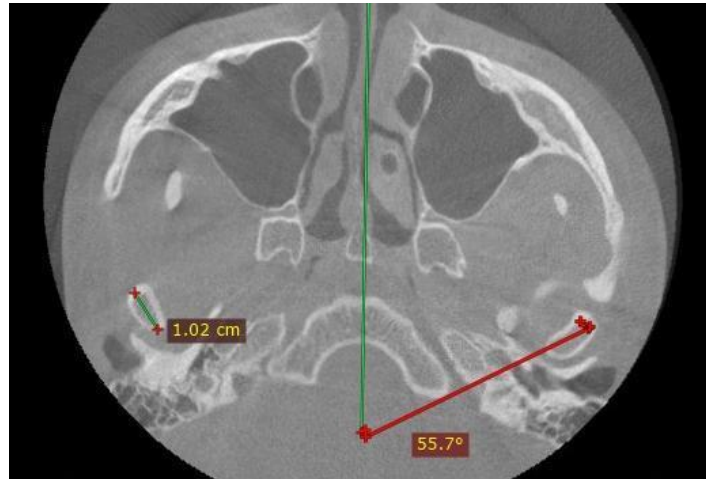


Figure 2: Major axis of the condyle in the axial plane and its angulation relative to the mid-sagittal plane

STATISTICAL ANALYSIS

The data was entered in Excel™ (Microsoft office 2010) and statistical analysis was performed with Statistical Package for Social Sciences (SPSS™. V. 17.0 Windows).

RESULTS

Regarding the position of the condyle in the glenoid cavity we found that the slightly anterior position of the condyle is the most frequent in people with type I and II malocclusion. The mean values and standard deviation of EAA, EAS and EAP on the right and left side are presented in (Chart 1); as well as the EAP/EAA and EAS/EAA ratios for both sides. The average differences between the right and left EAA were 0.04 mm ± 0.4; being 0.3 mm ± 0.4 for EAS and 0.4 m ± 0.4 for EAP. The average values and SD from the major axis of the condyle in its axial plane and its angulation regarding the sagittal plane are shown in (Chart 2).

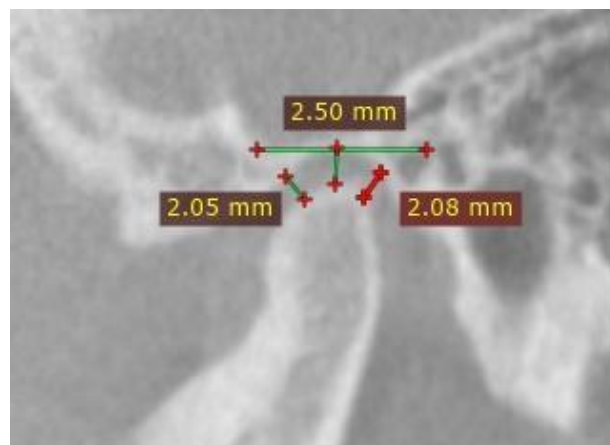


Figure 3: Measurements of joint spaces EAA, EAS and EAP



RECISATEC – REVISTA CIENTÍFICA SAÚDE E TECNOLOGIA
ISSN 2763-8405

EVALUATION OF THE CONDYLAR POSITION IN RELATION TO THE DIFFERENT MALOCCLUSIONS OF A STUDENT POPULATION
 Manuel Estuardo Bravo Calderón, Paula Lisseth Alberca Agreda, Monica Catalina Arias Astudillo,
 Diana Karolina Bustamante Granda, Nayeli Maldonado Alulima

MEASUREMENTS IN CM AND DE OF JOINT SPACES AND RATIOS ON RIGHT AND LEFT SIDES

ARTICULAR SPACES	CD MEDIA Y DE	CI MEDIA Y DE
EAA ¹	1.99	1.95
EAS ²	2.56	2.59
EAP ³	2.25	2.21
EAP/EAA ⁴	1.13	1.13
EAS/EAA ⁵	1.30	1.33

¹ Anterior joint space. ² Superior joint space ³ Posterior joint space. ⁴Ratio EAP/EAA ⁵RATIO EAS/EAA

AVERAGE VALUES OF THE MAJOR AXIS OF THE CONDYLES IN CM AND THEIR ANGULATION

VARIABLE	MEDIA (DS)
Eje CD ¹	1.46
Eje CI ²	1.43
Ángulo CD ³	64.27
Ángulo CI ⁴	67.5

¹ Right Condyle Mayor Axis. ² Left Condyle Mayor Axis. ³ Mayor Axis angle with sagittal plane

Chart 1

AVERAGE VALUES OF THE MAJOR AXIS OF THE CONDYLES IN CM AND THEIR ANGULATION

VARIABLE	MEDIA (DS)
Eje CD ¹	1.46
Eje CI ²	1.43
Ángulo CD ³	64.27
Ángulo CI ⁴	67.5

¹ Right Condyle Mayor Axis. ² Left Condyle Mayor Axis. ³ Mayor Axis angle with sagittal plane

AVERAGE IN MM (DE) OF THE MAJOR AXIS OF THE CONDYLE IN THE AXIAL PLANE AND ITS ANGULATION WITH RESPECT TO THE SAGITTAL PLANE

	CD (CM) MEDIA (DE)	CI MEDIA (DE)	P VALUE
Condilar distance	1.46	1.43	0.95
Condilar Angulation	64.27	67.5	0.86

¹ Righth Condyle. ²Left Condyle

Chart 2

DISCUSSION

A reliable and accurate diagnostic tool for morphological analysis of the TMJ is CBCT. The average difference between the repeated measurements in this study also indicates the accuracy of this technique for TMJ evaluation.

According to Soumalainen and Cols. (4), there are fewer errors in linear measurements performed with CBCT than in medical diagnosis.



RECISATEC – REVISTA CIENTÍFICA SAÚDE E TECNOLOGIA ISSN 2763-8405

EVALUATION OF THE CONDYLAR POSITION IN RELATION TO THE DIFFERENT MALOCCLUSIONS OF A STUDENT POPULATION
Manuel Estuardo Bravo Calderón, Paula Lisseth Alberca Agreda, Monica Catalina Arias Astudillo,
Diana Karolina Bustamante Granda, Nayeli Maldonado Alulima

The findings of our study showed that the largest joint space was the superior joint space, followed by the posterior joint space and the anterior joint space. These results show the same pattern as other investigations (1).

In a subdivision of malocclusion type II division 1 malocclusion, they observed the same pattern, which revealed that the most anterior position of the condyles in the socket is the most frequent position in type II malocclusions. Rodrigues and Cols (5) in a sample with type III malocclusion, observed a central position of the condyle, corresponding with our study that the superior articular space had the largest dimension.

The dimensions of the three condylar joint spaces were slightly larger on the left side than on the right. Al-Kosh and Cols (6) also observed this characteristic, but unlike ours, their study showed that the right condylar joint space was larger. This study found slightly larger joint space measurements and higher standard deviation values than those observed by Ikeda and Kawamura (3). This may be related to the specimen characteristics between the two studies, as Ikeda's specimen is a specimen with perfect occlusion, no central deviation and verification of normal articular disc position (1).

In our specimen, without examining the disc position, the condyles were expected to move away from the central relational position and increase the joint space measurements, so although we also found a mean ratio of the anterior condyle position of 1.13, this number is far from the ratio of 1.6 observed by Ikeda and Kawamura (3), observing a more anterior position of the condyle.

The EAP/EAA ratio, EAS/EAA ratio was 1.13 - 1.33 also differs from those observed by Dalili and cols (7) of 1.2 and 1.7 respectively and Kinniburgh (8), but neither paper used perfect specimens. Hansson et al (9) measured disc thickness in autopsy material and found that the average thickness of the anterior intermediate and posterior disc band was 2.0, 1.1 and 2.9 mm, these values are similar to this study. Extensive changes in the position of the condyle in the glenoid cavity in the anterior-posterior direction have been described (10). In this study, the anterior position of the condyle within the glenoid cavity was the most common position, although with a lower EAP/EAA ratio than the ideal occlusion (1).

CONCLUSION

The absence of condylar process centralization in the corresponding mandibular fossa was a common feature in the asymptomatic normal occlusion group, the anterior position of the condyle in the glenoid cavity being the most common position in asymptomatic subjects with type I and type II malocclusion.

The left condyle was found to be positioned slightly more anteriorly than the right. Although it was statistically significant only when comparing the normal and type II occlusion groups: type II patients have a higher position of the condyles in the glenoid fossa.

No statistically significant differences in fossa depth or glenoid fossa morphology were found between any of the malocclusions studied. Therefore, there is no significant difference between the axis and angle of both condyles.



RECISATEC – REVISTA CIENTÍFICA SAÚDE E TECNOLOGIA ISSN 2763-8405

EVALUATION OF THE CONDYLAR POSITION IN RELATION TO THE DIFFERENT MALOCCLUSIONS OF A STUDENT POPULATION
Manuel Estuardo Bravo Calderón, Paula Lisseth Alberca Agreda, Monica Catalina Arias Astudillo,
Diana Karolina Bustamante Granda, Nayeli Maldonado Alulima

REFERENCES

1. Pie de Hierro VVPM. Evaluacion de la posición condilar mediante tomografía computarizada de haz cónico en pacientes asintomáticos con maloclusión de clase I. Revista de la Sociedad Española. 2017 Enero;55(1).
2. Kurita HOAKK. 7. Kurita A study of the relationship between the position of the condylar head and displacement of the temporomandibular joint disk. Dentomaxillofac Radiol. 2001;30:162-165.
3. Iked KKA. Assessment of optimal condylar position with limited cone-beam computed tomography. J Orhod Dentofacial Orthop. 2009;135:495-501.
4. Soumalainen A VTKiMRS. Soumalainen Accuracy in measurements of distance using limited cone beam computerized tomography. Join Oral Maxillofac Radiol. 2008;37:10-17.
5. Rodrigues AF FMVR. Computed tomography evaluation of the temporomandibular joint in Class II Division1 and Class III malocclusion patients: Condylar symmetry and condyle-fossa relationship. Join Orhod Dentofacial Orthop. 2008;136:199-206.
6. Al -Koshab M MiPJJ. Assesment of condyle and glenoid fossa morphology using CBCT in South-East Asians. Plos One. 2015;10(3).
7. Dalili Z KNKSJSF. Assessing joint space and condylar position in the people with normal function of temporomandibular joint with cone-beam computed tomography.. Dalili Z, Khaki N, Kia S J, Salamat F. Assessing joint space and condylar position in the pDent Res J. 2012;9:607-612.
8. Kinniburgh RD MPNBWKGGrK. 8. Kinniburgh RD, Osseous morphology and spatial relationships of the temporomandibular joint: comparisons of normal and anterior disc positions. 8. Kinniburgh RD, Major PW, Nebbe B, West K, Glove r KE. Osseous morphology and spatial relationships oAngle Orthod. 2000;70:70-80.
9. Hansson T OrTCGKS. 9. Hansson Thickness of the soft tissue layers and the articular disk in temporomandibular joint. Acta Odontol. 1997;35:77-83.
10. Katzbe rg RW KDTEWGW. Internal derangement of temporomandibular joint: an assessment of the condylar position in centric occlusion. Join Prosthet Dent. 1983;49:250-254.